Curr Colorectal Cancer Rep (2013) 9:191–197
DOI 10.1007/s11888-013-0166-5

Irreversible Electroporation: a Novel Option for Treatment of Hepatic Metastases

Robert C. G. Martin II

Published online: 7 April 2013
© Springer Science+Business Media New York 2013

Abstract Irreversible electroporation (IRE) has shown promise for ablation of lesions in proximity to vital structures in the preclinical and now clinical setting. Studies of patients undergoing IRE for treatment of metastatic colorectal cancer to the liver were reviewed for patient and tumor characteristics, treatment-related complications, and local recurrence-free survival (LRFS) for ablated lesions. LRFS was calculated according to the Kaplan–Meier method, with secondary analyses stratified by procedural approach (laparotomy, laparoscopy, percutaneous) and tumor histological characteristics. Initial IRE success has been achieved in 95 % of treatments. The LRFS rates at 3, 6, and 12 months were 97.4 %, 94.6 %, and 59.5 %. There was a trend toward higher recurrence rates for tumors larger than 4 cm (hazard ratio 3.236, 95 % confidence interval 0.585-17.891; p=0.178). IRE is a safe and effective treatment for metastatic colorectal cancer to the liver near vital structures. Continued evaluation is needed to determine optimal probe design and techniques.

Keywords Metastatic colorectal cancer · Irreversible electroporation · Liver ablation

Introduction

Hepatic resection remains the most effective therapy for colorectal liver metastasis (CLM), with a greater than 5-year overall survival achieved in more than 50 % of patients. However, even in patients with liver-only disease, the location of that disease and/or poor underlying liver function mean that the number of patients who are candidates for this potentially curative approach is relatively small. In light of the limited applicability of surgical resection to many patients with CLM, a number of ablative technologies have been developed to provide liver-directed therapy. Among these are radiofrequency ablation (RFA) [1–3], ethanol ablation [4, 5], laser ablation [6–8], cryoablation [9], high-intensity focused ultrasound [10], microwave ablation [11, 12], and stereotactic body radiation therapy [13•].

These thermal ablative technologies all rely on transfer of thermal energy to the surrounding tissue for its effect. Similar limitations in relation to size and location have limited the use and effectiveness of these modalities. Studies of livers explanted after RFA have demonstrated that the rate of complete tumor necrosis falls below 50 % when there are vessels larger than 3 mm abutting the tumor, a consequence of the heat sink effect [14]. There is similar difficulty in achieving complete ablation for lesions in a subcapsular location or close to the gallbladder [15, 16]. Similar limitations around safety have also been demonstrated with the other thermal modalities in relation to lesions near vital structures (i.e., major bile ducts, portal vein, and hepatic veins). For patients who are not candidates for these thermal modalities, three-dimensional conformal radiation therapy has also been used [17, 18], although the median time to local recurrence with these modalities has been reported to be as early as 6.8 months [18].

Irreversible electroporation (IRE) is a promising new technology that may be able to overcome the problem of difficult tumor location faced by current ablative technologies. Rather than relying on thermal energy to induce necrosis, IRE delivers a series of electrical pulses of millisecond duration that create irreversible pores in cell membranes, leading to apoptosis [19, 20•]. The great promise of IRE is that the extracellular matrix is not permanently damaged, thus sparing the integrity of surrounding structures such as bile ducts and blood vessels [21]. Preclinical studies have demonstrated the potential efficacy of IRE in ablation of hepatocellular carcinoma in an animal model [22•]. Additional preclinical work by Bower et al. [20•]

R. C. G. Martin II (✉)
Department of Surgery, Division of Surgical Oncology, University of Louisville, 315 East Broadway, Suite 314, Louisville, KY 40202, USA
e-mail: robert.martin@louisville.edu

and Charpentier et al. [23, 24] has demonstrated that the electrical pulses do damage the cellular membrane of normal tissue (e.g., blood vessel endothelium, biliary epithelium); however, the collagenous structures remain intact. Intact adventitia and laminae are visible at 2 days, with no smooth muscle cells present [21]. The endothelium is largely repopulated at 2 days, with the smooth muscle repopulation at 2 weeks. This slow method of repopulation has been demonstrated in preclinical studies [20•] to allow vital structures to remain intact, patent, and viable for up to at least 1 month in both short-term and long-term animal studies as well as in human evaluation [25, 26]. The goal of this review is to present an evaluation of IRE for ablation of CLM in a clinical setting, to evaluate safety and efficacy, and to assess the lessons learned from this early experience that could serve as selection criteria for future protocolized studies.

Methods

Articles in the PubMed, Science Citation Index, and Embase databases from July 2005 to November 2012 were searched using the keywords "irreversible electroporation," "ablation," and "colorectal liver metastasis."

Ablation Procedure

Patients are reviewed in a multidisciplinary conference and when it is felt they are not amenable to resection or thermal ablation, use of IRE is evaluated. The commonest indication for IRE is unresectable involvement of the biliary hilum or the hepatic veins (Fig. 1).

IRE was performed in these studies using the NanoKnife system (AngioDynamics, Latham, NY, USA). The NanoKnife system consists of a computer-controlled pulse generator that delivers pulses of 1,500 V/cm (maximum 3,000 V) between a pair of IRE probes. Typically, a minimum of 90 pulses is delivered, and these last from 20 to 100 μs each. The commonest pulse length is 70–90 μs, with the shorter durations used in cases where high electrical resistance is encountered. The pulse voltages and duration are based on the findings of preclinical studies [20•, 23, 24]. Treatment planning is based on three-dimensional preoperative imaging with CT scanning in which the tumor dimensions and location of surrounding structures are measured (Fig. 1). From the preoperative scan, the tumor dimensions are input into the pulse generator, with a set planned margin. Multiple monopolar probes are used (maximum of six), with greater numbers of probes needed for larger ablation zones. The maximum effective probe spacing can range from 1.4 to 2.2 cm. If the probe spacing is either less than 1.4 cm or greater than 2.2 cm, then the effectiveness of the electroporation is reduced and this will lead to an incomplete ablation. The probes themselves are 19 gauge in diameter and radio-opaque to aid in intraprocedural identification of the probe tip. The maximum probe exposure used in liver IRE is 2–2.5 cm. Optimal technique requires the user place the needle along the longest axis of the tumor—most commonly the caudal to cranial plane (coronal plan)—and then perform sequential pullbacks to achieve both cranial and caudal margins. It is recommended not to attempt to perform the "overlapping ablation" technique that was first popularized with RFA, secondary to the fact that IRE therapy induces artifact and human error in ensuring precise spacing would lead to a greater incidence of ineffective therapy (i.e., reversible electroporation).

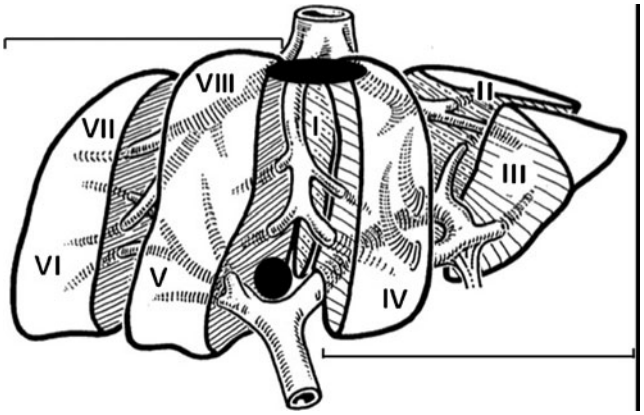

Fig. 1 Anatomic location of lesions where irreversible electroporation (IRE) plays the greatest role for tumor control (*black circle*)

The actual IRE procedure may be performed either percutaneously or in the operating room at the time of laparotomy or laparoscopy. Percutaneous cases are performed with CT guidance. In all cases, the patient must be under general anesthesia with deep neuromuscular blockade, which requires close collaboration with the anesthesiologist to achieve paralysis to zero twitches out of a train of four. This level of paralysis is needed to prevent patient movement when the high-voltage pulses are delivered.

The precise distance between probes is measured at the tip, and the probes must be placed within 10° of parallel for IRE to occur. Small deviations in probe placement can lead to areas of *reversible* electroporation which are likely to result in tumor recurrence. When multiple probe arrays are used, a mechanical guide is employed to maintain proper spacing and alignment. The probes are placed in a manner as to bracket the tumor, rather than violate the tumor itself (Figs. 2 and 3). The probes must also be completely encased in tissue to prevent arcing.

Delivery of the pulses is synchronized to the patient's ECG, which is a feature incorporated in the NanoKnife pulse generator. The pulses are timed to be delivered during the absolute myocardial refractory period 50 μs after the R wave in order to prevent generation of arrhythmias. Because of this synchronization, the patient must have a pulse rate

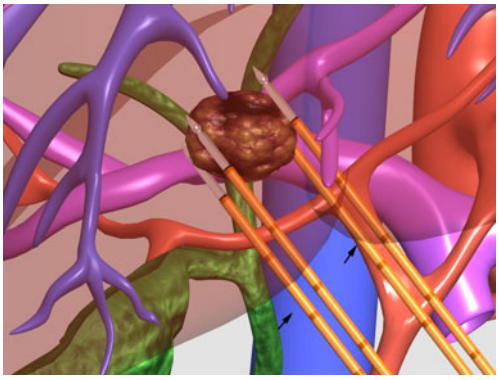

Fig. 2 Coronal graphic demonstration of appropriate needle placement for a hilar-based lesion and 4 IRE probes placement (*arrows*)

under 115. Higher pulse rates will cause the pulse generator to believe an arrhythmia is occurring and cease to deliver further pulses. During the procedure, the progress of the ablation is followed by tracking the actual current delivered. Given the changes in Ohm's law, the current delivered should sequentially increase throughout the procedure, as ablated tissue develops a lower resistance through nanopore formation.

The technical success of ablation was defined as the ability to successfully deliver all planned pulses (at least 90) in accordance with the size and dimensions of the lesion and see an appropriate rise in amperage delivered across these 90 pulses with a minimum delta of 10 A. The definition of proximity to major vascular/biliary structures or adjacent organs was defined as a distance of less than 5 mm (Fig. 1). Adverse events were recorded as per the established Common Terminology Criteria for Adverse Events (CTCAE) scale version 3.0. All complications were recorded prospectively at all institutions.

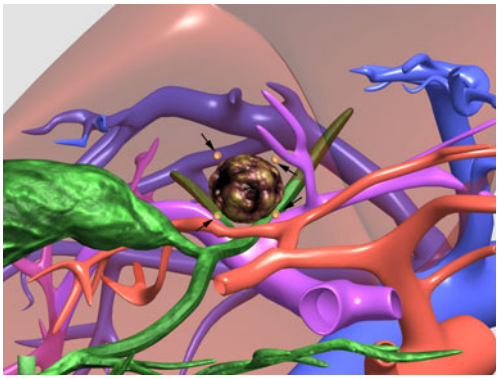

Fig. 3 Axial graphic demonstration of IRE needle placement of 4 IRE needle placement (*arrows*). The patients left inferior needle is placed in the left portion of the caudate lobe, the patient right inferior needle is placed 2 cm spacing and then placing 2 additional needles more anterior to make a square that has spacing of 2cm between each probe

Postprocedural Follow-up

It is recommended that follow-up imaging be performed at the time of discharge, only to assess vital structure patency, if necessary with first efficacy imaging being performed at 3 months. Ablation recurrence has been defined as persistent viable tumor as defined by dynamic imaging in comparison with the pre-IRE scan or tissue diagnosis. Ablation success was defined as the ability to deliver the planned therapy in the operating room and at 3 months for there to be no evidence of residual tumor as described above. The method of evaluating local recurrence was the use of cross-sectional imaging, either a CT scan or an MRI scan, with or without PET based on (1) the ability to obtain a preoperative PET scan and (2) the primary lesion in question having PET activity. In cases where a preoperative PET scan was obtained and the lesion was PET avid, persistent or recurrent PET avidity was evidence for tumor recurrence. Specific cutoffs for standardized uptake values to determine recurrence were not used. The use of CT versus MRI for follow-up can be left to the discretion of the treating physician. As noted above, general radiologic criteria for recurrence are new or persistent enhancement on multiphase imaging such as defined by the Response Evaluation Criteria in Solid Tumors (RECIST) [27].

In addition to imaging, standard tumor markers, including carcinoembryonic antigen for colorectal metastases, should be followed where appropriate. Although a diagnosis of recurrence should not be made on the basis of tumor markers alone, rising levels would lead to an imaging study. In cases where imaging was equivocal, biopsies were performed at the discretion of the treating physician.

Statistical Analysis

For the data, patient demographics, tumor characteristics, in-hospital outcomes, and local recurrence-free survival were examined. Continuous variables were summarized by median and interquartile range and were compared using the Wilcoxon–Mann–Whitney test, whereas categorical variables were summarized as count (percentage) and analyzed using the chi-squared test or Fisher's exact test, where appropriate. Local recurrence-free survival (LRFS) was determined from the time of ablation to radiographic recurrence of the treated lesion. Patients without evidence of recurrence were censored at the time of the last follow-up. Survival estimates were determined according to the method of Kaplan and Meier, with survival curves compared by the log-rank test. The relation of target lesion size to LRFS was determined according to Cox proportional hazards regression.

Results

A total of 45 patients have undergone IRE for ablation of CLM [28, 29•]. Of these patients treated, 20 were included in a recent report by Cannon et al. [29•], with this review adding 25 additional patients. All tumors were centrally located near major vascular/biliary structures or adjacent organs in all 45 patients (Figs. 4 and 5). The ablation procedure was performed percutaneously (n=25, 56 %), open (n=16, 36 %), or laparoscopically (n=4, 9 %). Technical success was achieved in 100 % of procedures.

All patients had received at least one or more forms of therapy and therapy had failed prior to the patients being referred for IRE. For all patients, at least one line of chemotherapy had failed, with most patients (80 %) receiving leucovorin/5-fluorouracil/oxaliplatin (FOLFOX) previously. Two patients were continuing to receive chemotherapy concomitant with a laparoscopic and percutaneous IRE procedure, one with 5-fluorouracil/bevacizumab/irinotecan and one with capecitabine/irinotecan/cetuximab. Twenty-one patients previously treated had prior liver-directed therapy, including six with ablation, ten with hepatic resection, three with three-dimensional conformal radiation therapy, and three with hepatic arterial therapy. Some patients were treated with multiple modalities prior to IRE.

The median length of stay following ablation was 1 day (outpatient to 5 days). Analysis of adverse events within 90 days of the procedure included a total of 11 adverse events that occurred after eight procedures (10 %). Two were deemed unrelated to the ablation (leukocytosis, urinary tract infection), four were categorized as indirectly related (dehydration, biliary stent occlusion, cholangitis due to biliary stent occlusion, and pleural effusion), and the remaining five were possibly procedure related (neurogenic bladder, abdominal pain, pneumonia, and flank pain). There were no treatment-related deaths. After a median follow-up of 12 months, there have been no late occurrences of biliary stricture or portal vein thrombosis.

Overall LFRS rates at 3, 6, and 12 months were 97.4 %, 94.6 %, and 58.5 %. Of the surviving patients, 50 % continued to receive some form of additional therapy (i.e., maintenance chemotherapy) in the form of Xeloda alone, 5-fluorouracil with Avastin, or Erbitux alone at the discretion of the treating medical oncologist. In addition to the local recurrences, there were 11

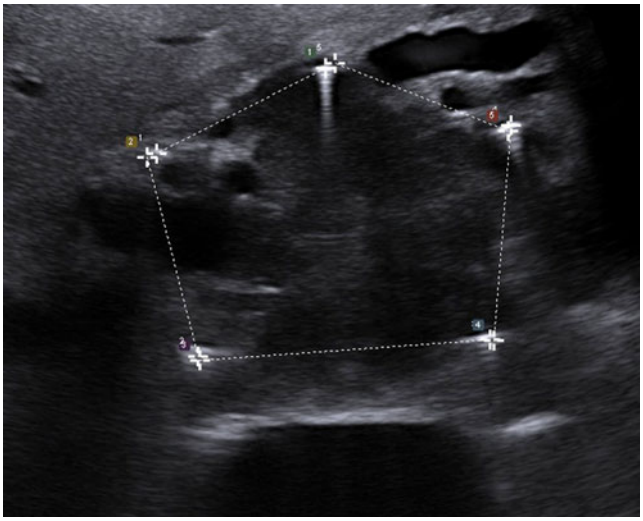

Fig. 5 Axial ultrasound imaging of a hilar-based lesion with two-dimensional size evaluated and recorded with five IRE needles in place with the spacing seen

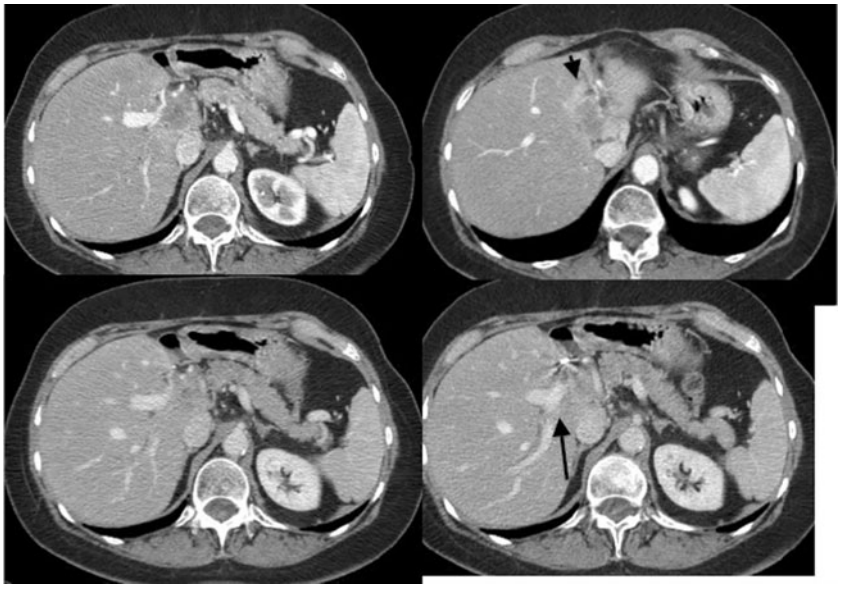

Fig. 4 Example of caudate-based lesion with invasion of both the left portal vein (*small arrow*) and te right posterior sectoral vein (*large arrow*)

distant recurrences: six in the lung, three in the peritoneum, and two in the bone. Median LRFS was not reached in any analysis. Examination of a plot of martingale residuals versus tumor size indicated a sharp increase at 3 cm, with maximum risk being attained at a tumor size of 4 cm. When Cox regression was used to compare LRFS in patients with tumors greater than 4 cm versus tumors less than 4 cm, the increased hazard ratio for larger tumors did not reach statistical significance (hazard ratio 3.236, 95 % confidence interval 0.585-17.891; p=0.178).

Change in tumor tissue resistance and the slope of the resistance curve were both also significant in predicting local recurrence (p=0.039 and p=0.040 respectively). Neither mean change in tumor tissue resistance nor the slope of the resistance curve significantly predicted distant recurrence-free survival (p=0.291 and p=0.283, respectively). Mean change in tumor tissue resistance and the slope of the resistance curve should be used intraoperatively to assess successful tumor ablation during IRE.

Discussion

IRE continues to show significant promise in the preclinical setting as well as in clinical use. In a rodent model of poorly differentiated hepatocellular carcinoma, Guo et al. [22•] demonstrated complete regression in 90 % of treated tumors. The major benefit of IRE compared with thermal ablative strategies is the ability to achieve ablation without damage to surrounding vital structures. Bower et al. [20•] performed ablation of pancreatic tissue in six swine, with the probes placed within 1 mm of either the portal vein or the superior mesenteric artery. Postoperatively, all animals recovered without any evidence of pancreatic necrosis or vascular thrombosis. Charpentier et al. [23] demonstrated the preclinical use of IRE near the hepatic hilum in another swine model. In this study, there was no evidence of a heat sink effect despite closeness to major vascular structures. Furthermore, there was no evidence of damage to the portal triad structures.

These preclinical studies provide a background of evidence suggesting that IRE may have a suitable role in the treatment of patients who are less than ideal candidates for current thermal ablative modalities owing to tumor location near vital structures. Thus far, the literature on clinical application of IRE has been sparse.

Similar results of IRE in the liver have been reported. Most series have a mix of histological features and thus pure CLM use has not been reported alone in any other series. The previous largest series of patients reported in the literature was described by Thomson et al. [30], in which 38 patients with tumors of the liver, kidneys, and lungs were treated by IRE. Initially, the procedure was performed without ECG synchronization, but resulted in transient ventricular arrhythmias in four patients. Following the introduction of ECG synchronization for the remaining 30 patients in the series, there was one case of transient supraventricular tachycardia and one case of transient atrial fibrillation. The other two treatment-related complications were transient hypertension resulting from inadvertent direct ablation of the adrenal gland, and ureteral obstruction. There was no other evidence of adjacent organ damage in the 69 tumors treated with IRE. Complete ablation was achieved in 46 of 69 patients (66 %), with most of the treatment failures occurring with renal and lung tumors. Of the 18 cases of hepatocellular carcinoma, complete ablation was achieved in 83 % of treated lesions. Notably, there was no evident response in liver metastases larger than 5 cm in any dimension.

Given the greater potential morbidity of an operative rather than a percutaneous procedure, there may have been a bias to perform operative IRE in patients with more indolent disease than in those who underwent a percutaneous procedure. However, because of the precision with which the IRE needles must be placed—i.e., within 10° of parallel or less, exactly with 1.7–2.2-cm spacing—the approach must be interpreted with caution, and must be performed in a manner in which the IRE delivery is not compromised. The recent published literature has clearly confirmed that IRE is indeed safe in the appropriate patient; however, efficacy cannot be compromised by the technical approach. The lack of randomization and a standardized protocol for patient selection makes these questions impossible to answer with the study at hand, however, and will require future prospective, protocolized studies.

The series reported in this article represent further evolution in the learning curve for clinical application of IRE. From our experience, there are two important lessons to be learned. First is the importance of ECG synchronization, which was employed for all patients, with no reported cases of treatment-related arrhythmias. Another is the role of tumor size. Thomson et al. [30] demonstrated no significant treatment effect for liver metastases larger than 5 cm. In this report, we demonstrate an increase in the risk of recurrence for tumors larger than 3–4 cm. We have also found that precise intraprocedural imaging is paramount to achieving complete ablation of target lesions, as misplacement of the probes by a margin of millimeters will result in viable tumor being left behind. A likely reason for the higher recurrence with tumors larger than 3–4 cm is the number of probes required to treat these large lesions. A 3-cm tumor is the largest that can be treated with a four-probe array. We do not currently believe that larger

probe arrays can be placed with the precision necessary to treat these larger tumors.

Because of the small number of patients in this series and the multiple operators and approaches, it would not be feasible to statistically assess the series for a learning curve, although we believe that for the open approach at least five cases are required for the operating surgeon to be adroit in both the technique and, just as importantly, the patient selection. A further five cases (ten in total) would be required for a laparoscopic approach, which is more difficult. In the percutaneous approach, given the requirement to be able to place multiple (at least three) needles perfectly parallel and with precise spacing, it is our feeling that five to seven cases are needed to gain comfort with the procedure. It is recommend for the initial user performing his/her first five procedures, that a *maximum* size of 3 cm be treated with IRE in order to ensure complete ablation and acceptable ablation recurrence (defined as less than 10 % of all tumors ablated). Once those quality criteria can be met, then ablating larger tumors (3–4 cm) is acceptable.

At this time, IRE appears to be best suited as salvage therapy for tumors less than 3–4 cm in diameter and situated in locations that make them poor candidates for treatment with thermal ablation. As such, the most appropriate comparator therapy is probably radiation therapy. In a study of 61 patients undergoing three-dimensional conformal radiation therapy for hepatocellular carcinoma under 5 cm in diameter, Lim et al. [17] demonstrated an initial complete response rate of only 44.3 %, with 32 % of patients experiencing nausea or vomiting and 4.9 % experiencing radiation-induced liver injury. In a study of radiation therapy for colorectal metastases in 17 patients, Krishnan et al. [18] demonstrated a 6-month LFRS rate of 62 %, with 29 % of patients experiencing diarrhea and 47 % experiencing nausea. The median time to local recurrence in the study of Krishnan et al. was 6.8 months.

Conclusion

The results presented here for IRE compare favorably with those presented for radiation therapy. Continued evaluation and more accurate intraoperative image guidance is critical to the necessary precision of probe placement. Finally, patients who are candidates for established ablative modalities such as RFA should not undergo IRE as first-line therapy because of the higher recurrence rates witnessed in these series. This study serves to provide preliminary data to guide future prospective clinical trials with this experimental technology. On the basis of the lessons learned here, appropriate inclusion criteria would be patients with hepatic tumors less than 3 cm in diameter who are not candidates for more traditional liver-directed therapies because of tumor location or in whom previous attempts with other therapies have failed.

Conflict of Interest Robert C.G. Martin II has received compensation from AngioDynamics for serving as a consultant.

References

Papers of particular interest, published recently, have been highlighted as:
- Of importance

1. Bruix J, Llovet JM. Prognostic prediction and treatment strategy in hepatocellular carcinoma. Hepatology. 2002;35:519–24.
2. Minami Y, Kudo M. Radiofrequency ablation of hepatocellular carcinoma: a literature review. Int J Hepatol. 2011;2011:104685.
3. Sindram D, Lau KN, Martinie JB, Iannitti DA. Hepatic tumor ablation. Surg Clin North Am. 2010;90:863–76.
4. Livraghi T, Goldberg SN, Lazzaroni S, Meloni F, Solbiati L, Gazelle GS. Small hepatocellular carcinoma: treatment with radio-frequency ablation versus ethanol injection. Radiology. 1999;210:655–61.
5. Shiina S, Tagawa K, Unuma T, Takanashi R, Yoshiura K, Komatsu Y, et al. Percutaneous ethanol injection therapy for hepatocellular carcinoma. A histopathologic study. Cancer. 1991;68:1524–30.
6. Vogl TJ, Mack MG, Muller PK, Straub R, Engelmann K, Eichler K. Interventional MR: interstitial therapy. Eur Radiol. 1999;9:1479–87.
7. Christophi C, Muralidharan V. Treatment of hepatocellular carcinoma by percutaneous laser hyperthermia. J Gastroenterol Hepatol. 2001;16:548–52.
8. Vogl TJ, Eichler K, Straub R, Engelmann K, Zangos S, Woitaschek D, et al. Laser-induced thermotherapy of malignant liver tumors: general principals, equipment(s), procedure(s) – side effects, complications and results. Eur J Ultrasound. 2001;13:117–27.
9. Ravikumar TS, Steele Jr GD. Hepatic cryosurgery. Surg Clin North Am. 1989;69:433–40.
10. Shen HP, Gong JP, Zuo GQ. Role of high-intensity focused ultrasound in treatment of hepatocellular carcinoma. Am Surg. 2011;77:1496–501.
11. Shibata T, Niinobu T, Ogata N, Takami M. Microwave coagulation therapy for multiple hepatic metastases from colorectal carcinoma. Cancer. 2000;89:276–84.
12. Yu NC, Lu DS, Raman SS, Dupuy DE, Simon CJ, Lassman C, et al. Hepatocellular carcinoma: microwave ablation with multiple straight and loop antenna clusters–pilot comparison with pathologic findings. Radiology. 2006;239:269–75.
13. • O'Connor JK, Trotter J, Davis GL, Dempster J, Klintmalm GB, Goldstein RM. Long-term outcomes of stereotactic body radiation therapy in the treatment of hepatocellular cancer as a bridge to transplantation. Liver Transpl. 2012;18:949–54. *This is one of the largest studies to report on stereotactic (intensity-modulated) radiation therapy, similar to CyberKnife therapy in the case of hepatic tumors*.
14. Lu MD, Xu HX, Xie XY, Yin XY, Chen JW, Kuang M, et al. Percutaneous microwave and radiofrequency ablation for hepatocellular carcinoma: a retrospective comparative study. J Gastroenterol. 2005;40:1054–60.

15. Komorizono Y, Oketani M, Sako K, Yamasaki N, Shibatou T, Maeda M, et al. Risk factors for local recurrence of small hepatocellular carcinoma tumors after a single session, single application of percutaneous radiofrequency ablation. Cancer. 2003;97:1253–62.
16. Kim SW, Rhim H, Park M, Kim H, Kim YS, Choi D, et al. Percutaneous radiofrequency ablation of hepatocellular carcinomas adjacent to the gallbladder with internally cooled electrodes: assessment of safety and therapeutic efficacy. Korean J Radiol. 2009;10:366–76.
17. Lim DH, Lee H, Park HC, Lee JA, Kim SW, Yoo BC, et al. The efficacy of high-dose 3-dimensional conformal radiation therapy in patients with small hepatocellular carcinoma not eligible for other local modalities. Am J Clin Oncol. 2012;1024:1024. doi:10.1097/COC.0b013e3182438dae.
18. Krishnan S, Lin EH, Gunn GB, Chandra A, Beddar AS, Briere TM, et al. Conformal radiotherapy of the dominant liver metastasis: a viable strategy for treatment of unresectable chemotherapy refractory colorectal cancer liver metastases. Am J Clin Oncol. 2006;29:562–7.
19. Lee RC. Cell injury by electric forces. Ann N Y Acad Sci. 2005;1066:85–91.
20. • Bower M, Sherwood L, Li Y, Martin R. Irreversible electroporation of the pancreas: definitive local therapy without systemic effects. J Surg Oncol. 2011;104:22–8. *This is the first report to demonstrate the safety of the use of IRE around vital blood vessels*.
21. Maor E, Ivorra A, Leor J, Rubinsky B. The effect of irreversible electroporation on blood vessels. Technol Cancer Res Treat. 2007;6:307–12.
22. • Guo Y, Zhang Y, Klein R, Nijm GM, Sahakian AV, Omary RA, et al. Irreversible electroporation therapy in the liver: longitudinal efficacy studies in a rat model of hepatocellular carcinoma. Cancer Res. 2010;70:1555–63. *This article is an additional report on the safety of IRE in the liver in an in vivo model*.
23. Charpentier KP, Wolf F, Noble L, Winn B, Resnick M, Dupuy DE. Irreversible electroporation of the liver and liver hilum in swine. HPB. 2011;13:168–73.
24. Charpentier KP, Wolf F, Noble L, Winn B, Resnick M, Dupuy DE. Irreversible electroporation of the pancreas in swine: a pilot study. HPB. 2010;12:348–51.
25. Martin 2nd RC, McFarland K, Ellis S, Velanovich V. Irreversible electroporation therapy in the management of locally advanced pancreatic adenocarcinoma. J Am Coll Surg. 2012;215:361–9.
26. Martin 2nd RC, McFarland K, Ellis S, Velanovich V. Irreversible electroporation in locally advanced pancreatic cancer: potential improved overall survival. Ann Surg Oncol. 2012;2424:2424. doi:10.1245/s10434-012-2736-1.
27. Eisenhauer EA, Therasse P, Bogaerts J, Schwartz LH, Sargent D, Ford R, et al. New response evaluation criteria in solid tumours: revised RECIST guideline (version 1.1). Eur J Cancer. 2009;45:228–47.
28. Niessen C, Jung EM, Stroszczynski C, Wiggermann P. Ablation einer Lebermetastase mit irreversibler Elektroporation (IRE) im Lebersegment II angrenzend an die Area nuda [Ablation of a liver metastasis with irreversible electroporation (IRE) in liver segment II adjoining the area nuda]. Rofo. 2012;184:937–8.
29. • Cannon R, Ellis S, Hayes D, Narayanan G, Martin 2nd RC. Safety and early efficacy of irreversible electroporation for hepatic tumors in proximity to vital structures. J Surg Oncol. 2012;2424:2424. doi:10.1002/jso.23280. *This is the largest study of the use of IRE for ablation of hepatic tumors close to vital structures with long-term 12-month follow-up*.
30. Thomson KR, Cheung W, Ellis SJ, Federman D, Kavnoudias H, Loader-Oliver D, et al. Investigation of the safety of irreversible electroporation in humans. J Vasc Interv Radiol. 2011;22:611–21.